

# Journal of Child Neurology

<http://jcn.sagepub.com>

---

## **Critical Illness Polyneuromyopathy in a Child with Severe Demyelinating Myelitis**

Tanja Adamovic, Ariane Willems, Michel Vanasse, Guy D'Anjou, Yves Robitaille, Catherine Litalien and France Gauvin

*J Child Neurol* 2009; 24; 758 originally published online Mar 4, 2009;  
DOI: 10.1177/0883073808330166

The online version of this article can be found at:  
<http://jcn.sagepub.com/cgi/content/abstract/24/6/758>

---

Published by:



<http://www.sagepublications.com>

**Additional services and information for *Journal of Child Neurology* can be found at:**

**Email Alerts:** <http://jcn.sagepub.com/cgi/alerts>

**Subscriptions:** <http://jcn.sagepub.com/subscriptions>

**Reprints:** <http://www.sagepub.com/journalsReprints.nav>

**Permissions:** <http://www.sagepub.com/journalsPermissions.nav>

**Citations** <http://jcn.sagepub.com/cgi/content/refs/24/6/758>

# Critical Illness Polyneuromyopathy in a Child With Severe Demyelinating Myelitis

Tanja Adamovic, MD, Ariane Willems, MD, Michel Vanasse, MD, Guy D'Anjou, MD, Yves Robitaille, MD, Catherine Litalien, MD, and France Gauvin, MD, MSc

We report a child presenting with severe demyelinating myelitis complicated with critical illness polyneuropathy. This previously healthy 8-month-old boy presented with acute superior limb weakness, absent tendon reflexes, and respiratory failure. Spinal magnetic resonance imaging showed an extensive cervical demyelinating lesion. Spinal cord trauma was suspected and high doses of dexamethasone were administered. Electromyography and nerve conduction studies showed absence of compound muscle action potentials and sural nerve sensory action potential, which was suggestive of a severe Guillain-Barré syndrome. However, intravenous

immunoglobulins did not induce any improvement. Afterward, sural nerve biopsy showed a mild neuropathy, but muscle biopsy revealed abnormalities compatible with severe critical illness myopathy. After 5 months of evolution without improvement, the patient died following withdrawal of life support therapy. This case highlights the possible occurrence of critical illness polyneuromyopathy when treatment with corticosteroids are used in patients with acute demyelinating myelitis.

**Keywords:** critical illness; polyneuropathies; transverse myelitis; neuromuscular diseases; demyelinating disease

Critical illness polyneuropathy and critical illness myopathy represent a continuum of intensive care unit (ICU)-acquired weakness and have now been called critical illness polyneuromyopathy.<sup>1</sup> Critical illness polyneuromyopathy is a potentially severe and rarely reported complication of critical illness in children. It is most frequently associated with multiple organ dysfunction syndrome and sepsis,<sup>1-3</sup> though other possible risk factors have been identified and include administration of corticosteroids, neuromuscular blocking agents or aminoglycosides, hyperglycemia, status asthmaticus, organ and bone marrow transplantation, burns, poor control of glycemia, and malnutrition.<sup>2,4-8</sup>

Received July 23, 2008. Received revised October 15, 2008. Accepted for publication October 16, 2008.

From the Division of Pediatric Critical Care, Department of Pediatrics (TA, AW, CL, FG), Division of Neurology, Department of Pediatrics (MV, GD), Department of Pathology (YR), CHU Sainte-Justine, Université de Montréal, Montréal, Québec, Canada.

We thank Stephane Dedelis for his invaluable assistance with the photography. The authors have no conflicts of interest to disclose with regard to this article.

Address correspondence to: France Gauvin, Division of Pediatric Critical Care, Hôpital Sainte-Justine, 3175 Côte Ste-Catherine, Room 3406, Montréal, Québec, Canada H3T 1C5; e-mail: [france\\_gauvin@sss.gouv.qc.ca](mailto:france_gauvin@sss.gouv.qc.ca).

Adamovic T, Willems A, Vanasse M, et al. Critical illness polyneuromyopathy in a child with severe demyelinating myelitis. *J Child Neurol*. 2009;24:758-762.

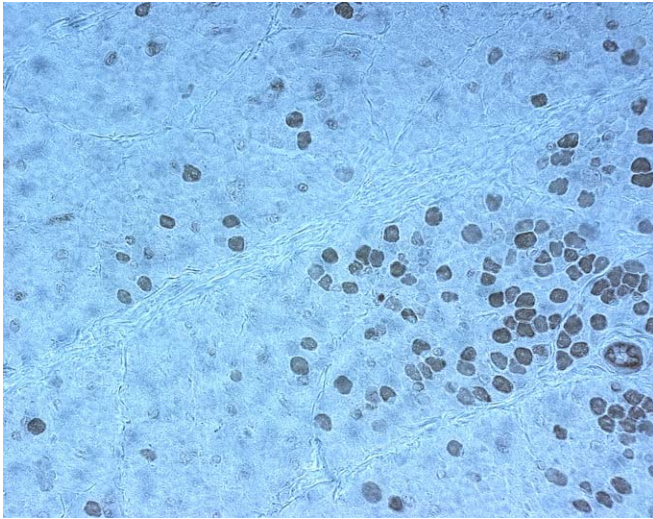
Diagnosis of intensive care unit-acquired weakness is sometimes difficult because of other conditions presenting with similar clinical signs and symptoms and similar neurophysiologic abnormalities, particularly in the axonal variant of Guillain-Barré syndrome.<sup>9-11</sup>

Demyelinating or acute transverse myelitis is another neurological condition rarely encountered in children. It consists of a focal disorder of the spinal cord, resulting in motor, sensory, and autonomic dysfunction,<sup>12</sup> spreading sometimes to several spinal segments,<sup>13</sup> with a presumed inflammatory demyelinating etiology, for which there is no prior history of a demyelinating event.<sup>14</sup>

Until now there is no report in the adult or pediatric literature of the association of critical illness polyneuromyopathy and acute central nervous system demyelinating disease such as transverse myelitis. We therefore report a case of a child presenting with severe demyelinating myelitis complicated with critical illness polyneuromyopathy early in his evolution and discuss diagnostic, clinical, and therapeutic implications of this association.

## Case Report

Our patient was an 8-month-old Caucasian boy, previously healthy, who presented with flaccid paralysis of his superior limbs after a fall from his height. Three weeks earlier he had a cold, and 2 weeks before hospitalization he received a vaccine against influenza virus. At admission,



**Figure 1.** Muscle biopsy;  $\times 400$ , adenosine triphosphatase pH 9.4. There is a very extensive loss of sarcomeric myosin, with few normally stained fibers along the edge. Type II fiber atrophy is present.

he had decreased deep tendon reflexes of his superior extremities and required immediate intubation for respiratory failure due to respiratory muscle weakness. A cerebral magnetic resonance imaging study was normal, whereas spinal magnetic resonance imaging demonstrated swelling of the cervical spinal cord from C1 to T1 with a mass effect and with high signal intensity on T2 sequence located centrally. Initially, a diagnosis of incomplete centromedullary spinal cord injury without radiographic abnormality affecting the C1 to C7 region was retained, and the child was consequently treated with high doses of dexamethasone followed by prolonged weaning. Despite corticosteroids, his neurological condition progressively deteriorated within the next few days, and he developed flaccid quadriplegia, diffuse loss of deep tendon reflexes followed by occurrence of clonus, loss of pain sensitivity, and development of horizontal nystagmus. However, he always preserved a normal state of consciousness. Two courses of intravenous immune globulins were administered without any clinical improvement. Repeated magnetic resonance imaging over the next weeks showed progression of the spinal lesion up to the medulla oblongata with increased mass effect, which eventually evolved to severe spinal atrophy from C2 to T1.

A week after admission, nerve conduction studies showed no motor response after median nerve stimulation, and no sensory nerve action potential after sural nerve stimulation suggesting a severe demyelinating or axonal type of Guillain-Barré syndrome associated with a medullar lesion. Despite treatment, electrophysiologic deterioration continued to progress, showing diffuse absence of compound motor action potential after motor

median, peroneal, and tibial nerve stimulation, and no sensory nerve action potential on sural nerve stimulation 3 weeks after admission. An extensive microbiology investigation was performed with all results negative. Hematological, biochemical, metabolic, and vasculitic workups were normal as well as acute inflammatory markers and cerebrospinal fluid findings. Serum creatine kinase levels were equally normal. Similarly, ophthalmologic evaluation revealed no signs of optic neuritis.

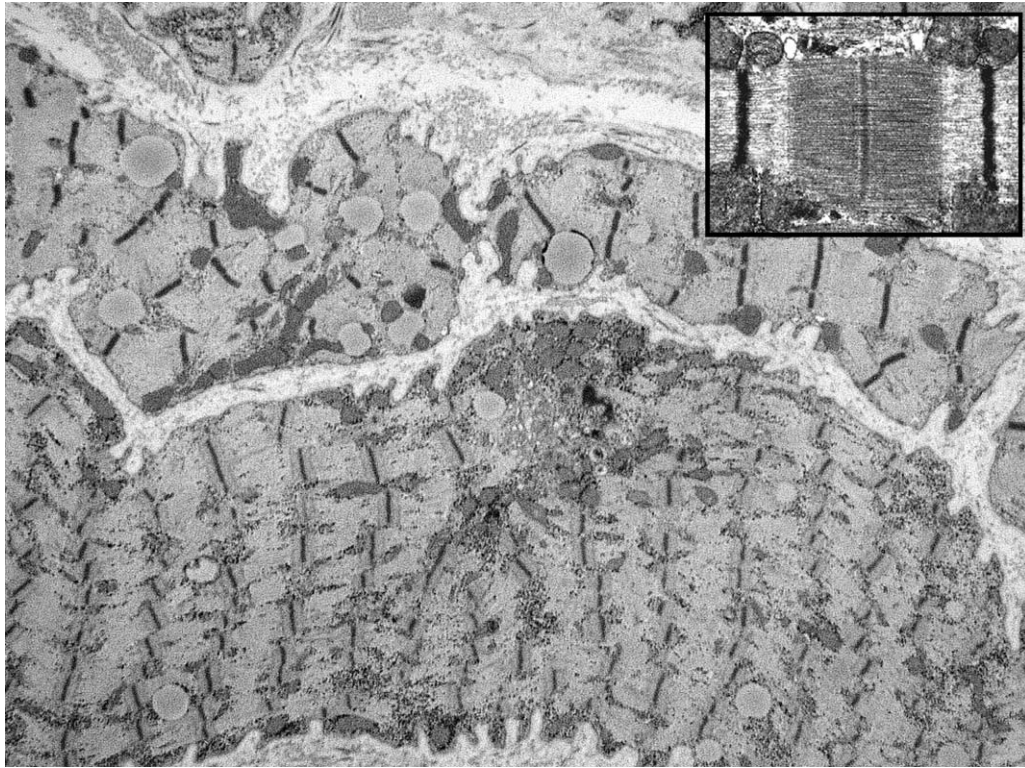
Due to the atypical and prolonged course of the disease, a nerve and a muscle biopsies were performed. The muscle biopsy was characterized by extensive myosin loss without necrosis or regeneration and without abnormalities suggestive of denervation, which was compatible with critical illness myopathy (Figures 1 and 2). On the sural nerve biopsy, slight signs of axonal neuropathy were associated with multifocal, mild, recent demyelination probably secondary to axonal lesions. However, there was no endoneurial inflammation compatible with autoimmune inflammatory neuropathy like Guillain-Barré syndrome.

Prolonged course in the pediatric intensive care unit (5 months) was complicated with several nosocomial infections and unsuccessful attempts of mechanical ventilation weaning. The patient died after a decision to withdraw life support therapy.

## Discussion

Intensive care unit–acquired weakness was first described more than 20 years ago in the adult population.<sup>15</sup> Since that time, several reports of intensive care unit–acquired weakness have been published mainly in adults,<sup>5,16-26</sup> highlighting common risk factors and delineating the extent of injury.

Although well recognized in adults, intensive care unit–acquired weakness was only occasionally reported in children, and little is known on its prevalence, etiology, clinical significance, and risk factors in this population. A recent review article by Williams et al<sup>27</sup> summarizes the pediatric literature on intensive care unit–acquired weakness consisting of 12 reports of this condition in 20 children<sup>6,28-37</sup> and 1 recent prospective study with 14 patients.<sup>38</sup> Among the 34 cases of intensive care unit–acquired weakness reported, none was associated with central nervous system demyelinating disease (eg, transverse myelitis, acute disseminated encephalomyelitis, etc). Intensive care unit–acquired weakness is usually described in critically ill patients in the presence of more than 1 risk factor, including administration of nondepolarizing neuromuscular blocking agent and high-dose corticosteroids.<sup>39</sup> However, some patients have been exposed neither to drug nor to only 1 of 2.<sup>40,41</sup> Although many of the reported children were treated with corticosteroids and neuromuscular blocking agents before the onset of



**Figure 2.** Muscle biopsy;  $\times 4400$ , representative ultrastructural microphotograph of sarcomeres. There is a widespread loss of myosin filaments, compared with normal sarcomeres (inset).

weakness, it is not possible from the data presented to derive any causative association between these factors, as no controlled study is available.

Although the confirmed or assumed potential adverse effects of high-dose corticosteroids are numerous, they remain a treatment of choice for several severe diseases<sup>42</sup> due to their powerful immunomodulatory actions. Despite the absence of prospective controlled trials, high-dose corticosteroids remain the first-line treatment for acute autoimmune central nervous system demyelination including transverse myelitis, acute disseminated encephalomyelitis, and optic neuritis.<sup>43-46</sup>

Our patient suffered from severe demyelinating myelitis and consequently was treated with high-dose corticosteroids. Neurological findings at admission were explained by spinal shock. Yet, despite proven spinal cord lesion, clinical findings were always suggestive of lower motor neuron lesions. Neurophysiologic studies obtained early in the course of hospitalization showed abnormalities, which were suggestive of a severe peripheral nervous system injury and specifically a severe demyelinating or axonal form of Guillain-Barré syndrome or critical illness polyneuromyopathy.<sup>9,10</sup> The diagnosis of Guillain-Barré syndrome was retained on the basis of these neurophysiologic abnormalities early in the course of the disease and

the absence of myopathic abnormalities on electromyography, findings not unusual in cases of critical illness polyneuromyopathy.<sup>47</sup> Although electromyography and nerve conduction velocities can reveal abnormalities in patient with critical illness polyneuromyopathy, nerve and muscle biopsies remain the gold standard for establishing the nature and severity of nerve and muscle pathology but is not routinely performed because it is invasive.<sup>47-49</sup>

Although historically considered extremely rare especially in children, recent reports in adults<sup>50</sup> and children<sup>51</sup> point to coexistence of peripheral nervous system autoimmune inflammation (Guillain-Barré syndrome) and acute autoimmune central nervous system demyelination (transverse myelitis, acute disseminated encephalomyelitis, etc), which is more frequent than previously thought. Despite the fact that in both series the peripheral nervous system involvement was characterized mainly by a demyelinating pattern in nerve conduction velocity studies, significant amount of patients presented principally neurophysiologic characteristics of axonal injury (34.6% in adult series<sup>50</sup> and 46% in pediatric series<sup>51</sup>), unusual finding for the Guillain-Barré syndrome in Western countries.<sup>52,53</sup> An additional unexplained finding is poor evolution and long-term outcome of patients with combined central and peripheral nervous system demyelination compared with

patients with isolated central nervous system demyelination,<sup>50,51</sup> or isolated Guillain-Barré syndrome,<sup>51,54</sup> despite the immunomodulatory treatment used. Nevertheless, in our patient, neurophysiologic studies did not permit to differentiate between Guillain-Barré syndrome and critical illness polyneuromyopathy. As nerve and muscle biopsies are infrequently performed in intensive care unit settings, the real nature of those axonal injuries, unfortunately, remains undetermined.

## Conclusion

Our patient presented with severe demyelinating myelitis complicated with critical illness polyneuromyopathy. This case highlights the necessity of high index of suspicion for possible development of critical illness polyneuromyopathy when high-dose corticosteroid treatment is administered in patients with acute central nervous system demyelinating diseases. Despite the utility of neurophysiologic studies, nerve and muscle biopsy should be considered in patients in whom the diagnosis of critical illness polyneuromyopathy is not entirely clear. Although first-line treatment for acute central nervous system demyelination consists of high-dose corticosteroids with prolonged weaning, it might be more beneficial to avoid or rapidly wean this therapy in patients with concomitant axonal type of peripheral nervous system lesion while waiting for the results of nerve/muscle biopsy; relay could be made with other immunomodulatory treatment like intravenous immunoglobulins.

Future prospective studies are needed to evaluate efficient noninvasive diagnostic tools for critical illness polyneuromyopathy, delineate its epidemiology, risk factors, possible treatment options, and evolution in the pediatric population.

## References

- Latronico N, Fenzi F, Recupero D, et al. Critical illness myopathy and neuropathy. *Lancet*. 1996;347:1579-1582.
- Berek K, Margreiter J, Willeit J, Berek A, Schmutzhard E, Mutz NJ. Polyneuropathies in critically ill patients: a prospective evaluation. *Intensive Care Med*. 1996;22:849-855.
- Tennila A, Salmi T, Pettila V, Roine RO, Varpula T, Takkunen O. Early signs of critical illness polyneuropathy in ICU patients with systemic inflammatory response syndrome or sepsis. *Intensive Care Med*. 2000;26:1360-1363.
- Deem S, Lee CM, Curtis JR. Acquired neuromuscular disorders in the intensive care unit. *Am J Respir Crit Care Med*. 2003;168:735-739.
- de Letter MA, Schmitz PI, Visser LH, et al. Risk factors for the development of polyneuropathy and myopathy in critically ill patients. *Crit Care Med*. 2001;29:2281-2286.
- Tabarki B, Coffinieres A, Van Den Bergh P, Huault G, Landrieu P, Sébire G. Critical illness neuromuscular disease: clinical, electrophysiological, and prognostic aspects. *Arch Dis Child*. 2002;86:103-107.
- Fletcher SN, Kennedy DD, Ghosh IR, et al. Persistent neuromuscular and neurophysiologic abnormalities in long-term survivors of prolonged critical illness. *Crit Care Med*. 2003;31:1012-1016.
- van den Berghe G, Wouters P, Weekers F, et al. Intensive insulin therapy in the critically ill patients. *N Engl J Med*. 2001;345:1359-1367.
- Hund E. Critical illness polyneuropathy. *Curr Opin Neurol*. 2001;14:649-653.
- de Letter MA, Visser LH, van der Meche FG, Ang W, Savelkoul HF. Distinctions between critical illness polyneuropathy and axonal Guillain-Barre syndrome. *J Neurol Neurosurg Psychiatry*. 2000;68:397-398.
- Yuki N, Hirata K. Relation between critical illness polyneuropathy and axonal Guillain-Barre syndrome. *J Neurol Neurosurg Psychiatry*. 1999;67:128-129.
- MCWG T. Proposed diagnostic criteria and nosology of acute transverse myelitis. *Neurology*. 2002;59:499-505.
- Pidcock FS, Krishnan C, Crawford TO, et al. Acute transverse myelitis in childhood: center-based analysis of 47 cases. *Neurology*. 2007;68:1474-1480.
- Krupp LB, Banwell B, Tenembaum S. Consensus definitions proposed for pediatric multiple sclerosis and related disorders. *Neurology*. 2007;68(suppl 2):S7-S12.
- Bolton CF, Gilbert JJ, Hahn AF, Sibbald WJ. Polyneuropathy in critically ill patients. *J Neurol Neurosurg Psychiatry*. 1984;47:1223-1231.
- Bolton CF, Lavery DA, Brown JD, Witt NJ, Hahn AF, Sibbald WJ. Critically ill polyneuropathy: electrophysiological studies and differentiation from Guillain-Barre syndrome. *J Neurol Neurosurg Psychiatry*. 1986;49:563-573.
- Zochodne DW, Bolton CF, Wells GA, et al. Critical illness polyneuropathy. A complication of sepsis and multiple organ failure. *Brain*. 1987;110:819-841.
- Lacomis D, Giuliani MJ, Van Cott A, Kramer DJ. Acute myopathy of intensive care: clinical, electromyographic, and pathological aspects. *Ann Neurol*. 1996;40:645-654.
- Rich MM, Raps EC, Bird SJ. Distinction between acute myopathy syndrome and critical illness polyneuropathy. *Mayo Clin Proc*. 1995;70:198-200.
- Lacomis D, Zochodne DW, Bird SJ. Critical illness myopathy. *Muscle Nerve*. 2000;23:1785-1788.
- Witt NJ, Zochodne DW, Bolton CF, et al. Peripheral nerve function in sepsis and multiple organ failure. *Chest*. 1991;99:176-184.
- De Jonghe B, Sharshar T, Lefaucheur JP, et al. Paresis acquired in the intensive care unit: a prospective multicenter study. *JAMA*. 2002;288:2859-2867.
- Zochodne DW, Ramsay DA, Saly V, Shelley S, Moffatt S. Acute necrotizing myopathy of intensive care: electrophysiological studies. *Muscle Nerve*. 1994;17:285-292.
- Helliwell TR, Coakley JH, Wagenmakers AJ, et al. Necrotizing myopathy in critically-ill patients. *J Pathol*. 1991;164:307-314.
- Helliwell TR, Wilkinson A, Griffiths RD, McClelland P, Palmer TE, Bone JM. Muscle fibre atrophy in critically ill patients is associated with the loss of myosin filaments and the presence of lysosomal enzymes and ubiquitin. *Neuropathol Appl Neurobiol*. 1998;24:507-517.

26. Coakley JH, Nagendran K, Honavar M, Hinds CJ. Preliminary observations on the neuromuscular abnormalities in patients with organ failure and sepsis. *Intensive Care Med.* 1993;19:323-328.
27. Williams S, Horrocks IA, Ouvrier RA, Gillis J, Ryan MM. Critical illness polyneuropathy and myopathy in pediatric intensive care: a review. *Pediatr Crit Care Med.* 2007;8:18-22.
28. Chetaille P, Paut O, Fraisse A, Kreitmann B, Camboulives J, Pellissier JF. Acute myopathy of intensive care in a child after heart transplantation. *Can J Anaesth.* 2000;47:342-346.
29. Sheth RD, Pryse-Phillips WE, Riggs JE, Bodensteiner JB. Critical illness neuromuscular disease in children manifested as ventilatory dependence. *J Pediatr.* 1995;126:259-261.
30. Heckmatt JZ, Pitt MC, Kirkham F. Peripheral neuropathy and neuromuscular blockade presenting as prolonged respiratory paralysis following critical illness. *Neuropediatrics.* 1993;24:123-125.
31. Kaplan PW, Rocha W, Sanders DB, D'Souza B, Spock A. Acute steroid-induced tetraplegia following status asthmaticus. *Pediatrics.* 1986;78:121-123.
32. Benzing G III, Iannaccone ST, Bove KE, Keebler PJ, Shockley LL. Prolonged myasthenic syndrome after one week of muscle relaxants. *Pediatr Neurol.* 1990;6:190-196.
33. Panegyres PK, Squier M, Mills KR, Newsom-Davis J. Acute myopathy associated with large parenteral dose of corticosteroid in myasthenia gravis. *J Neurol Neurosurg Psychiatry.* 1993;56:702-704.
34. Dimachkie MM, Austin SG, Slopis JM, Vriesendorp FJ. Critical illness polyneuropathy in adolescence. *J Child Neurol.* 1995;10:409-411.
35. Tsao CY, Lo WD, Mendell JR, Batley RJ. Critical illness polyneuropathy in a 2-year-old girl with hemorrhagic shock encephalopathy syndrome. *J Child Neurol.* 1995;10:486-488.
36. Petersen B, Schneider C, Strassburg HM, Schrod L. Critical illness neuropathy in pediatric intensive care patients. *Pediatr Neurol.* 1999;21:749-753.
37. Pascucci RC. Prolonged weakness after extended mechanical ventilation in a child. *Crit Care Med.* 1990;18:1181-1182.
38. Banwell BL, Mildner RJ, Hassall AC, Becker LE, Vajsar J, Shemie SD. Muscle weakness in critically ill children. *Neurology.* 2003;61:1779-1782.
39. Sanap MN, Worthley LI. Neurologic complications of critical illness: part II. Polyneuropathies and myopathies. *Crit Care Resusc.* 2002;4:133-140.
40. Hirano M, Ott BR, Raps EC, et al. Acute quadriplegic myopathy: a complication of treatment with steroids, nondepolarizing blocking agents, or both. *Neurology.* 1992;42:2082-2087.
41. Showalter CJ, Engel AG. Acute quadriplegic myopathy: analysis of myosin isoforms and evidence for calpain-mediated proteolysis. *Muscle Nerve.* 1997;20:316-322.
42. Bennetto L, Scolding N. Inflammatory/post-infectious encephalomyelitis. *J Neurol Neurosurg Psychiatry.* 2004;75(suppl 1):i22-i28.
43. Tenenbaum S, Chitnis T, Ness J, Hahn JS. Acute disseminated encephalomyelitis. *Neurology.* 2007;68(suppl 2):S23-S36.
44. Arnold AC. Evolving management of optic neuritis and multiple sclerosis. *Am J Ophthalmol.* 2005;139:1101-1108.
45. Boomer JA, Siatkowski RM. Optic neuritis in adults and children. *Semin Ophthalmol.* 2003;18:174-180.
46. Kerr DA, Ayetey H. Immunopathogenesis of acute transverse myelitis. *Curr Opin Neurol.* 2002;15:339-347.
47. Hund E. Myopathy in critically ill patients. *Crit Care Med.* 1999;27:2544-2547.
48. Bolton CF. Sepsis and the systemic inflammatory response syndrome: neuromuscular manifestations. *Crit Care Med.* 1996;24:1408-1416.
49. Bolton CF. Critical illness polyneuropathy and myopathy. *Crit Care Med.* 2001;29:2388-2390.
50. Marchioni E, Ravaglia S, Piccolo G, et al. Postinfectious inflammatory disorders: subgroups based on prospective follow-up. *Neurology.* 2005;65:1057-1065.
51. Adamovic T, Riou EM, Bernard G, et al. Acute combined central and peripheral nervous system inflammatory demyelination in children. *Pediatr Neurol.* 2008;39:307-316.
52. Kuwabara S. Guillain-Barre syndrome: epidemiology, pathophysiology and management. *Drugs.* 2004;64:597-610.
53. Hund EF. Neuromuscular complications in the ICU: the spectrum of critical illness-related conditions causing muscular weakness and weaning failure. *J Neurol Sci.* 1996;136: 10-16.
54. Ryan MM. Guillain-Barre syndrome in childhood. *J Paediatr Child Health.* 2005;41:237-241.