

Multiple Evanescent White Dot Syndrome After Vaccination for Human Papilloma Virus and Meningococcus

Steven M. Cohen, MD

ABSTRACT

Multiple evanescent white dot syndrome is a rare chorioretinopathy causing transitory vision loss, usually in females and generally in one eye. In 2007, widespread vaccination of older children against human papilloma virus and meningococcus was recommended by the Centers for Disease Control and Prevention. A 17-year-old girl presented with multiple evanescent white dot syndrome 1 month after receiving these two vaccinations. [J Pediatr Ophthalmol Strabismus 200X;XX:XX-XX.]

INTRODUCTION

Patients with multiple evanescent white dot syndrome (MEWDS), a rare chorioretinopathy, usually present with mild to moderate vision loss, central and paracentral scotomata, and floaters.¹ Signs and symptoms of MEWDS are evanescent, usually lasting 4 to 6 weeks. Most patients experience a flu-like illness approximately 1 month before the onset of visual symptoms. In the initial report of MEWDS by Jampol et al.² in 1984, 10 of 11 patients were women 20 to 38 years old. The youngest known patient to have MEWDS was 10 years old.³ There has also been a report of MEWDS after hepatitis A vaccination and hepatitis B vaccination.^{4,5}

In March 2007, the Centers for Disease Control and Prevention Advisory Committee on Immunization Practices recommended the human papilloma virus (HPV) vaccine for all girls 11 to 12 years old and for girls and women 13 to 26 years old who have not yet been vaccinated.^{6,7} The HPV vaccine is administered as a series in a three-dose

schedule.⁸ In August 2007, the Advisory Committee recommended meningococcal conjugate vaccine for all individuals 11 to 18 years old.⁹ To the author's knowledge, this report is the first to describe a case of MEWDS in an adolescent girl who had recently received these two vaccinations.

CASE REPORT

A previously healthy 17-year-old girl with myopia reported central and paracentral dark shimmering spots in the vision of her left eye for 3 days. The right eye was normal. She had received her first HPV and meningococcal vaccination 1 month before the onset of visual loss. She had no history of fever or flu-like symptoms within the past year. She denied any health problems and had no family history of vision problems. She had no history of neurologic problems and no pain on eye movement. The patient's maternal grandmother had psoriasis and severe rheumatoid arthritis.

Best-corrected Snellen visual acuity was 20/20 in the right eye and 20/200 in the left eye. There was no afferent pupillary defect. Amsler grid testing of the left eye showed central and paracentral scotoma. Findings on slit-lamp examination were normal except for 1+ anterior vitreous cells in the left eye. Fundus examination of the left eye showed slight blurring of the optic disc margin, loss of the foveal reflex, 1+ posterior vitreous cells, and rare small white spots in the macula and nasal periphery (Fig. 1). Humphrey 30-2 visual field testing showed enlargement of the blind spot in the left eye (Fig. 2). Fluorescein angiography of the left eye showed

From the University of South Florida School of Medicine, Tampa, Florida.

Originally submitted July 10, 2008. Accepted for publication October 29, 2008.

The author has no financial or proprietary interest in the materials presented herein.

Address correspondence to Steven M. Cohen, MD, 579 South Duncan Avenue, Clearwater, FL 33756.

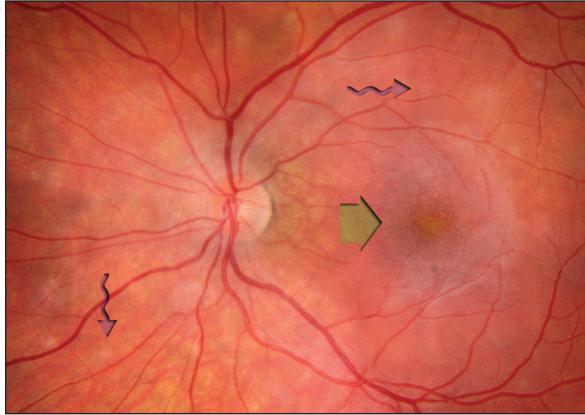


Figure 1. Fundus photograph of the normal right eye and abnormal left eye. The foveal reflex of the left eye is blunted. Arrows show white spots in the left eye. **AQ2**

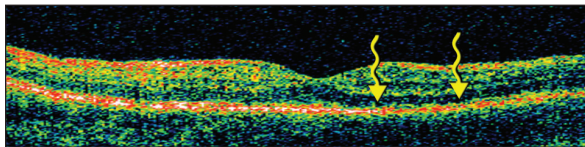


Figure 3. Optical coherence tomography line scans of the normal right macula and abnormal left macula. The right retina has a normal double red line (red arrows) at the external limiting membrane of the photoreceptor–retinal pigment epithelial interface. The left retina shows irregularities at the level with a loss of the double red line (white arrows). **AQ3**

subtle hyperfluorescent spots corresponding to the white spots seen on funduscopy. Optical coherence tomography of the left eye showed loss of normal architecture of the deep retina (Fig. 3).¹⁰ Findings on examination and testing of the right eye were normal. The patient was HLA-B27–positive, but was not HLA-B51–positive.¹¹

On follow-up examination 2 months after the initial evaluation, visual acuity had improved to 20/20 in the left eye and the Humphrey 30-2 visual field was normal.

DISCUSSION

Because the HPV vaccine is new, there is concern that its implementation will be followed by temporally related events that are mistakenly assumed to be caused by the vaccine.¹² The association of the current patient’s MEWDS with the HPV and meningococcal vaccines could be coincidental. Both of these vaccines are administered to young women, and MEWDS occurs predominantly in young women.

On the other hand, MEWDS is rare and often occurs after a flu-like syndrome. Interestingly,

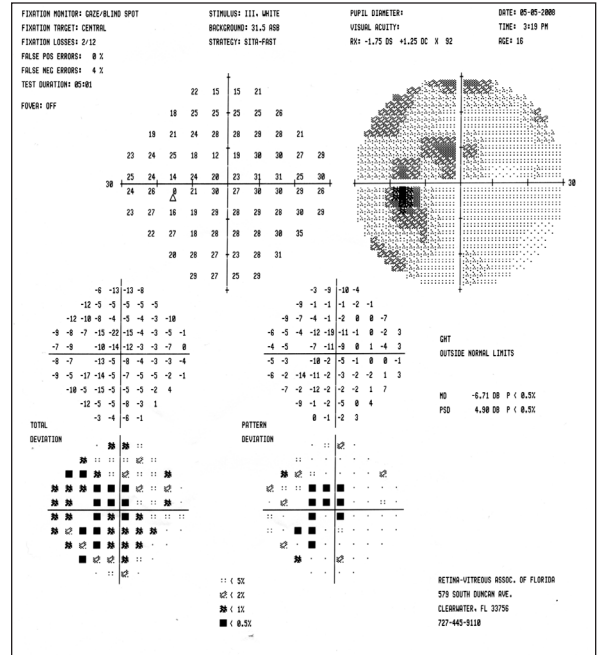


Figure 2. Humphrey visual field examination of the left eye showing enlargement of the blind spot with scotoma that touches fixation.

the interval between the vaccinations and the onset of symptoms in this patient was similar to the interval between a viral prodrome and the onset of MEWDS previously reported in more than 50% of cases.²

Although the etiology of MEWDS is unknown, infectious and autoimmune-mediated inflammatory mechanisms have been proposed. Because MEWDS often occurs in patients after a flu-like illness and can occur after vaccinations, an autoimmune-mediated inflammatory mechanism could explain the onset of MEWDS in this patient. Autoimmunity incited by a vaccine could occur in the presence of molecular mimicry. This occurs when an antigen in a vaccine is structurally similar to an antigen in the host and antibodies are produced that react with the host’s normal tissue.¹³

Widespread use of the HPV and meningococcal vaccines began this year.**AQ1** If either of these vaccines causes MEWDS, more cases like this one will likely occur.

REFERENCES

- Gross NE, Yannuzzi LA, Freund KB, Spaide RF, Amato GP, Sigal R. Multiple evanescent white dot syndrome. *Arch Ophthalmol.* 2006;124:493-500.
- Jampol LM, Sieving PA, Pugh D, Fishman GA, Gilbert H. Multiple evanescent white dot syndrome. *Arch Ophthalmol.* 1984;102:671-674.

3. Olitsky SE. Multiple evanescent white-dot syndrome in a 10-year-old child. *J Pediatr Ophthalmol Strabismus*. 1998;32:288-289.
4. Fine L, Fine A, Cunningham ET. Multiple evanescent white dot syndrome following hepatitis A vaccination. *Arch Ophthalmol*. 2001;119:1856-1857.
5. Baglivo E, Sfran AV, Borruat FX. Multiple evanescent white dot syndrome after hepatitis B vaccine. *Am J Ophthalmol*. 1996;122:431-432.
6. Markowitz LE, Dunne EF, Saraiya M, et al. Quadrivalent human papillomavirus vaccine: recommendations of the Advisory Committee on Immunization Practices (ACIP). *MMWR Recomm Rep*. 2007;56(RR-2):1-24.
7. Pichichero ME. Who should get the HPV vaccine? *J Fam Pract*. 2007;56:197-202.
8. Harper DM, Franco EL, Wheeler C, et al. Efficacy of a bivalent L1 virus-like particle vaccine in prevention of infection with human papillomavirus types 16 and 18 in young women: a randomized controlled trial. *Lancet*. 2004;364:1731-1732.
9. Centers for Disease Control and Prevention Advisory Committee on Immunization Practices. Revised recommendations of the Advisory Committee on Immunization Practices to vaccinate all persons aged 11-18 years with meningococcal conjugate vaccine. *MMWR Morb Mortal Wkly Rep*. 2007;56:794-795.
10. Nguyen MHT, Witkin AJ, Reichel E, et al. Microstructural abnormalities in MEWDS demonstrated by ultrahigh resolution optical coherence tomography. *Retina*. 2007;27:414-418.
11. Desarnaulds AB, Borruat FX, Herbort CP, Spertini F. Le multiple evanescent white dot syndrome: one predisposition genetique? *Klin Monatsbl Augenheilkd*. 1996;208:301-302.
12. Siegrist CA, Lewis EM, Eskola J, Evans SJ, Black SB. Human papilloma virus immunization in adolescent and young adults: a cohort study to illustrate what events might be mistaken for adverse reactions. *Pediatr Infect Dis J*. 2007;26:979-984.
13. Waisbren BA. Acquired autoimmunity after viral vaccination is caused by molecular mimicry and antigen complementarity in the presence of an immunologic adjuvant and specific HLA patterns. *Med Hypotheses*. 2008;70:346-348.

AUTHOR QUERIES

AQ1 Please specify year (2008?).

AQ2 The caption refers to both eyes but only one image is provided. Is this correct? Also, please differentiate between straight and wavy arrows.

AQ3 The caption mentions red and white arrows but only yellow arrows are visible. Please clarify. Also, the caption refers to both eyes but only one image is provided. Is this correct?